

Spotlight on Safety Story

Title of Spotlight on Safety Story: : *Learning from neonatal clinical incidents: oesophageal perforation in the extremely preterm infant*

Name & Role: Rob Tinnion, Consultant Neonatologist^a, Claire Granger, Neonatal Higher Specialist Trainee^a, Richard Hearn, Consultant Neonatologist^a

Acknowledgement: Kathryn Worcester, NHS England and NHS Improvement

Workplace: ^aWd35 NICU, Royal Victoria Infirmary, Newcastle upon Tyne, NE3 1AL.

Email / Tel: robert.tinnion@nuth.nhs.uk 0191 2825635

Do you wish your name / unit to be removed before circulation to BAPM members?: No

Situation	Two preterm infants were referred to a regional surgical centre with possible oesophageal atresia and suspected oesophageal perforation from attempted insertion of gastric tubes.
Background	<p>These infants were born extremely preterm in NICU centres and there had been difficulties with insertion of gastric tubes following multiple intubation attempts at the time of delivery. Neither baby was considered to have an anatomically difficult airway.</p> <p>In both cases the projected course of the gastric tube is unusual (radiographs 1: Case 1; radiograph 2&3: Case 2]. In Case 1, the gastric tube and subsequently passed replegle tube would not advance and a diagnosis of oesophageal atresia was suspected. In radiograph 1, the gastric tube projects clearly to the left of the midline along the level of the cervical vertebrae despite the film being well centred. In Case 2 the gastric tube was difficult to pass and drainage of a right-sided pneumothorax was required. In the radiograph 2, the gastric tube remains persistently to the right of the midline, is not below the diaphragm, and is unusually straight in its course. In radiograph 3 the tube lies in the right posterior diaphragmatic recess. The presence of pneumothorax in Case 2 prompted consideration there was an oesophageal pouch which had been perforated by the passage of a gastric tube. Water soluble contrast was passed down the gastric tube and showed spread into the thoracic cavity consistent with oesophageal perforation. In neither case had a suitable aspirate been obtained after passage of the gastric tube to confirm the tip lay in an acidic milieu.</p>

Assessment	<p>At the surgical centre, the radiographs for Case 1 were reviewed and a small amount of contrast passed down the replegle which did not delineate the full length of the oesophagus. The baby was therefore taken to theatre for operative exploration and found to have an oesophageal perforation. The perforation was oversewn, the baby was nursed nil-by-mouth for a period of time to allow healing and nutritional needs were met with TPN given via PICC. A conservative approach was taken with Case 2: the gastric tube was removed, nutritional needs met with TPN and antibiotic cover provided to prevent intrathoracic infection. No oesophageal pouch was found in either case.</p> <p>Unfortunately in both cases, the baby died suddenly of complications of prematurity not thought to be directly related to the oesophageal perforation.</p> <p>Independent of these two cases, NHS England and NHS Improvement (NHSE/I) undertook a review in 2019 of the National Reporting and Learning System (NRLS) for reported incidents</p>
-------------------	---

	<p>of perforation of the oesophagus in neonates¹. The review found 15 reported incidents in the preceding 3 years relating to iatrogenic oesophageal perforation and occurring either during intubation, insertion of gastric tube, or on occasions where both were done. Of the 15 events, 7 babies required surgical intervention, 4 had conservative management and in 4 further management was not specified. From the information provided in the incident reports there was no clear relationship with presence of an introducer within the endotracheal tube at the time of intubation, though a common feature through the reported cases was difficulty in completing the procedure (intubation or passing the gastric tube).</p> <p>Literature specific to preterm neonates is sparse but a single case report from 2013⁽¹⁾ suggests that there is a potentially high mortality with perforation of the oesophagus in an older population (up to 28%) and the causative event is likely to be either attempted endotracheal intubation or gastric tube insertion (between 71-84% of recognised perforations). The true incidence is unknown but as oesophageal perforation may go unrecognised or unreported where relatively uneventful recovery is made, the 15 cases found through a review of the NRLS is likely to be an underestimate. The authors of the case report suggest conservative management (gastric tube removal and PN until healed) with confirmation of healing by contrast instillation may be the best approach for preterm babies. Surgery in extremely preterm babies can be challenging and they may not tolerate operative intervention as well as older children. In addition, neonates generally heal rapidly, making conservative management more feasible.</p>
<p>Recommendation</p>	<ol style="list-style-type: none"> 1. In extreme preterm babies, great care should be taken when inserting both gastric and endotracheal tubes. If difficulties are encountered, undue force must not be used. 2. For extremely preterm babies at delivery, intubation and passing gastric tubes should be done by, or under the close supervision of, the most experienced team member present: repeated attempts at both intubation and passing a gastric tube by inexperienced staff should be avoided. 3. All organisations should ensure compliance with the national Patient Safety Alert (NHS/PSA/RE/2016/006) from 2016² regarding the safe placement and risks of harm from placement of gastric tubes. They should ensure that staff have been assessed as competent to place gastric tubes to the standards outlined in the NHS Improvement Resource Set³ accompanying the 2016 PSA. 4. The utility of technology such as videolaryngoscopy (VL) should be considered on a unit-by-unit basis. VL has been shown to improve rates of 1st pass intubation and by implication reduction of unintended harm from oesophageal intubation. 5. When reviewing radiographs of babies in which there was a 'difficult' tube placement the course of the gastric tube should be examined, specifically considering the thoracic course, for potential perforation of the oesophagus. The gastric tube course on properly-centred, plain, chest radiographs should not deviate/loop outside the margins of the oesophagus or traverse the thorax to the right of the midline. Where this is seen, oesophageal perforation should be suspected. 6. There is no specific evidence that stylet/introducer use in endotracheal intubation is related to an increased incidence of oesophageal perforation when unintended oesophageal intubation occurs, but clinicians using these devices should have been trained to do so safely. Specifically, the tip of the stylet should not extend beyond the tip of the endotracheal tube.

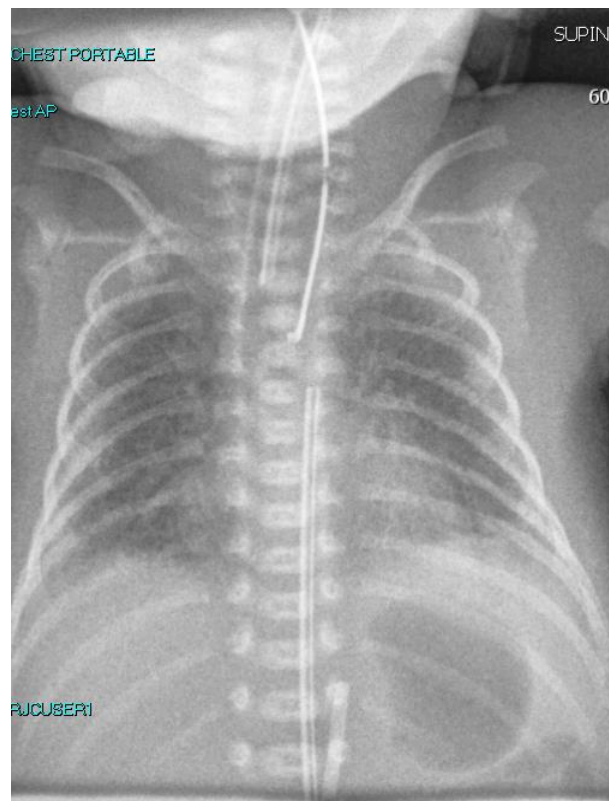
¹ NRLS Data extracted 6th June 2019; Search period of incident dates from 6th June 2016 if uploaded to NRLS before 6th June 2019; keywords 'oesophag' and 'perforat'. Filters used to include all incidents with a reported categorical age range of <28 days. All incidents with no categorical age stated were reviewed, and judgements of age made according to the descriptions, and excluded on that basis. There were no incidents where it was not possible to determine criteria for inclusion or exclusion.

	<ol style="list-style-type: none">7. A small amount of water soluble contrast may be used for confirmation of intrathoracic placement of the gastric tube tip if oesophageal perforation is suspected.8. Conservative management should be considered as first line where possible (on a case-by-case basis), with removal of the gastric tube, use of parenteral nutrition and antibiotics to allow healing. Healing of the perforation after 7 days can be confirmed by instilling water soluble contrast (oesophagography) or successful subsequent passage of a gastric tube (with radiographs and aspiration of gastric contents to confirm intragastric tube tip position).
--	--

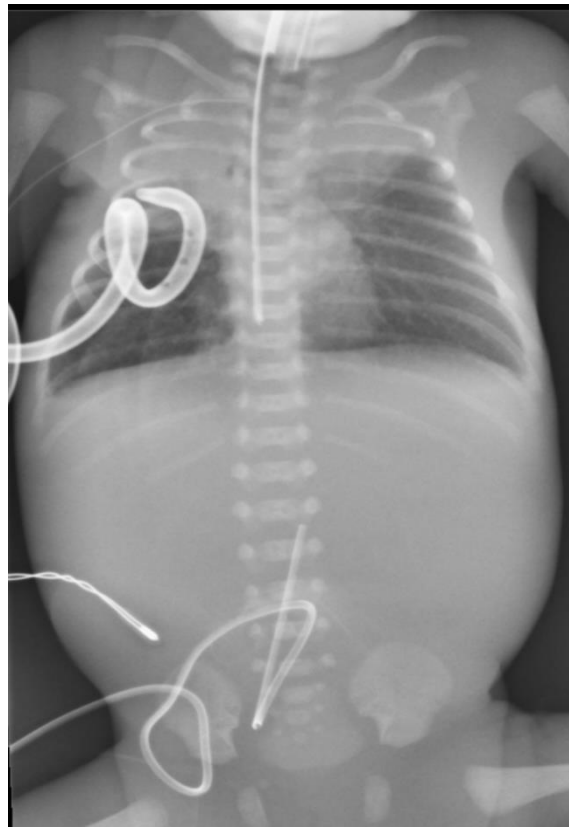
Reference

1. Sticco, A. et al. Iatrogenic esophageal perforation in a premature neonate: a current nonoperative approach to management. J Paed Surg Case Reports. (2); 2014:pp 37-39
2. https://www.england.nhs.uk/wp-content/uploads/2019/12/Patient_Safety_Alert_Stage_2_-_NG_tube_resource_set.pdf
3. [Resource set: initial placement checks for nasogastric and orogastric tubes](#)

Radiograph 1 (Case 1): gastric tube taking extreme left lateral course in the neck then down through the thoracic inlet



Radiograph 2 (case 2): Gastric tube following deviated course to the right of the spine, towards the right diaphragmatic recess



Radiograph 3 (Case 2): Gastric tube tracking to the right of the spine as it traverses mediastinum into the diaphragmatic recess, importantly not curling where projected below the level of the diaphragm.

